

Chapter 2



PEDIATRIC CARDIAC ISSUES HOW THE HEART FUNCTIONS, CONGENITAL HEART DEFECTS AND THEIR TREATMENT

THE HUMAN HEART

The heart is a marvellous combination of functional simplicity and systemic complexity. It is, on the one hand, simply a large muscle specifically designed to pump blood through the blood vessels of the body. On the other hand, its importance, while self-evident in one respect (if it does not work, you die) is hidden in many others (if it does not work perfectly, your health can be compromised in less-obvious ways).

The functioning of all other organs and systems within the body depends on an adequate blood supply. One example of this is the brain. Reduction or impairment in its supply of blood can result in a loss of neurological function, a loss of consciousness, or even death. One can, of course, appreciate what a sudden and sustained loss of blood supply can do to someone. But impairment in blood circulation can progress so slowly and over such a long period of time that, while its impact can be serious, its consequences may be difficult to detect. Problems can occur if the heart's ability to function adequately is even slightly impaired. Slow deterioration in cardiac performance can cause an equally slow deterioration in other organ performance. Thus, diagnosing even a minor condition that impairs the heart's performance is important. While one's life may not be immediately threatened by a minor impairment, ultimately one's life can be seriously affected and even shortened by the eventual deterioration and failure of other life-sustaining organs, such as the lungs, the kidneys and the liver. The heart, therefore, plays a central role in sustaining the optimal performance of all other organs and bodily systems. The heart must perform its function in such a way as to enable all other organs of the body to perform their tasks.

The heart muscle even sustains itself. In pumping blood, the blood vessels of the heart, the coronary arteries, are themselves filled with blood. The heart muscle is thereby nourished, allowing it to continue to perform its pumping.

The heart performs a vital balancing act with each contraction. It pushes blood in two major directions—to the lungs and to the body. Blood flows to the lungs through the pulmonary arteries and from the lungs

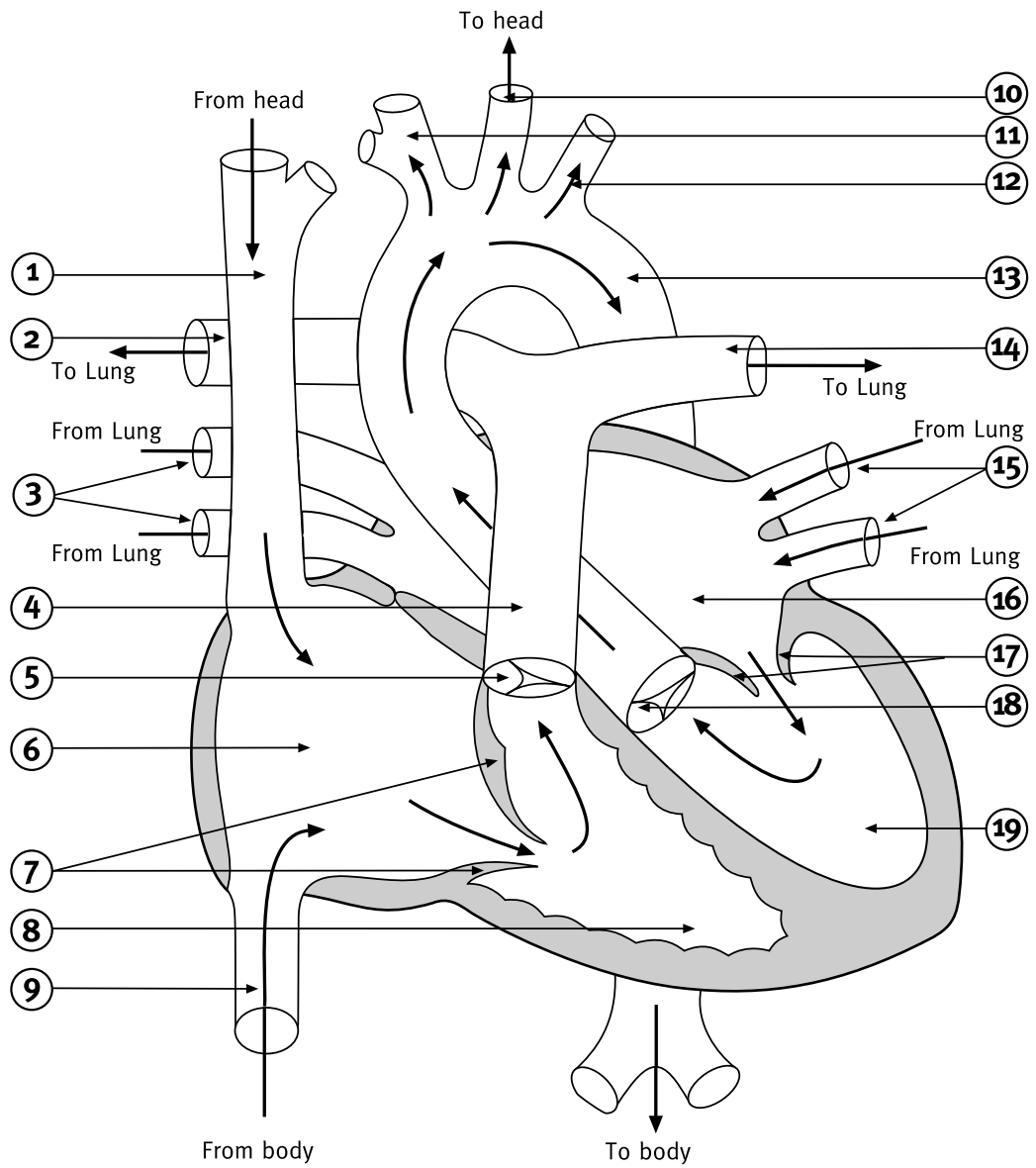


Diagram 2.1 Normal Heart (with blood flow)

- | | |
|--|-----------------------------|
| 1 - Superior vena cava | 11 - Innominate artery |
| 2 - Right pulmonary artery | 12 - Left subclavian artery |
| 3 - Right pulmonary veins | 13 - Aorta |
| 4 - Pulmonary artery (pulmonary trunk) | 14 - Left pulmonary artery |
| 5 - Pulmonary valve | 15 - Left pulmonary veins |
| 6 - Right atrium | 16 - Left atrium |
| 7 - Tricuspid valve | 17 - Mitral valve |
| 8 - Right ventricle | 18 - Aortic valve |
| 9 - Inferior vena cava | 19 - Left ventricle |
| 10 - Left common carotid artery | |

through the pulmonary veins, in what is referred to as the pulmonary circulation. Blood flows to the body through arteries and their smaller branches and from the rest of the body in veins and their smaller branches. This is known as the systemic circulation. The amount of blood flow needs to be equal through the left and right sides of the heart and through the systemic and pulmonary circulations.

HOW A NORMAL HEART WORKS

The normal heart consists of four chambers: two upper atria (singular: atrium) and two lower ventricles. The atria are the collecting chambers of the heart, into which blood flows from the body and the lungs. The atria pump blood into the ventricles, although the force of the atrial pumping action is not as strong as that of the ventricles. These are the stronger pumping chambers, responsible for moving blood to the lungs and to the body. Of the two ventricles, the right ventricle is not as strong a pump as is the left ventricle. The right ventricle only pumps blood through the lungs or pulmonary circulation, which has a low resistance and therefore requires less pressure than the left ventricle, which pumps blood around the entire rest of the body. Thus although the amount of flow needs to be equal through the right and left sides of the heart, the pressures are quite different on the two sides.

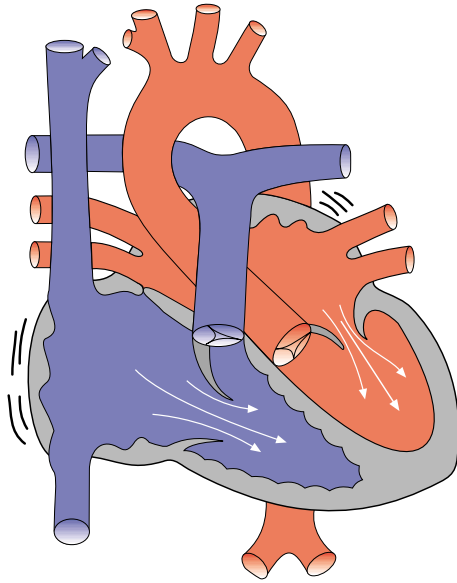
Blood flows from the body into the right atrium. That blood is 'blue' and is in need of oxygen, because oxygen has been removed from the blood by the body's organs and muscles in the course of blood flow. This blood is referred to as venous blood. It then passes from the right atrium into the right ventricle, which pumps the blood through the pulmonary arteries to the lungs where the blood picks up a fresh supply of oxygen. The oxygenated or 'red' blood then returns to the heart, flowing from the lungs through the pulmonary veins to the left atrium. The oxygenated blood next passes into the left ventricle, from where it is pumped through the aorta to the body.

The heart has three major vessels that bring blood to and take blood from it. The superior vena cava (SVC) and the inferior vena cava (IVC) are the two largest venous vessels that connect to the right atrium. The SVC returns the blood from the head and upper body to the heart to be oxygenated, while the IVC does the same for the lower body. The aorta is the major arterial vessel that takes blood from the heart. The left ventricle pumps all the oxygenated blood through the aorta to the body.

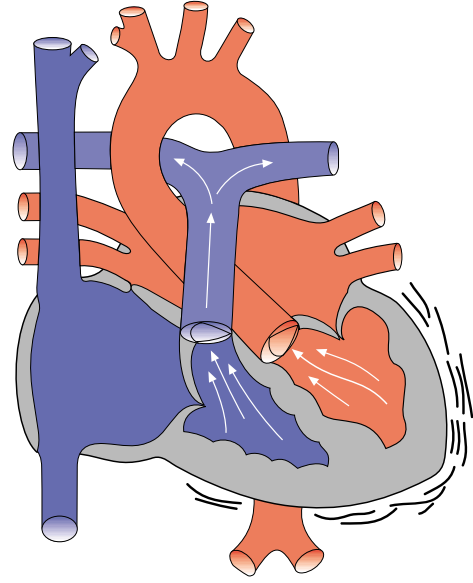
As blood flows through each of the four chambers of the heart, valves open and close in precise sequence. In the normally functioning heart, this allows blood to flow forward into the next chamber and prevents it from flowing backward. If a valve is defective, then blood can sometimes flow backward through it. When blood flows backwards through a valve, this is known as regurgitation.

There are four valves in the heart. The mitral valve and the tricuspid valve separate the heart's upper and lower chambers. The tricuspid valve separates the right atrium from the right ventricle, while the mitral valve separates the left atrium from the left ventricle. These valves are known as the atrioventricular valves.

The pulmonary valve separates the right ventricle from the pulmonary artery, which is the main blood vessel connecting the heart to the lungs. The aortic valve separates the left ventricle from the aorta. It is the closing of all four valves which produces the heart beat sound with its familiar 'lub -dub'.

**Diagram 2.2 Heart contracting - atrial contractions**

Atria contract, forcing blood out.
Force of blood opens inflow valves
and blood enters ventricles.

**Diagram 2.3 Heart contracting - ventricular contractions**

Ventricles contract, forcing blood out.
Force of blood opens outflow valves and closes
inflow valves.

When heard with a stethoscope, heart murmurs sound like soft whooshing noises that follow or replace the normal sounds of the heart's action. Murmurs may indicate that blood is leaking through an imperfectly closed valve and may signal the presence of a serious heart problem.

The contractions of the heart are actually more complex than the simple squeezing of a bag. In effect, the heart contracts in rhythm, with the left ventricle contracting slightly ahead of the right ventricle. These contractions occur so closely together that one can think of them as one contraction, but that is not actually the case.

The wall of the heart consists of three distinct layers—the epicardium (outer layer), the myocardium (middle layer) and the endocardium (inner layer). The myocardium actually causes the heart to contract, as its muscle fibres create a wringing movement that efficiently squeezes blood from the heart with each beat. The thickness of the myocardium varies according to the pressure generated to move blood to its destination. Thus the myocardium of the left ventricle is thicker than the myocardium of the right ventricle. The endocardium lines the cavities of the heart, covering the valves, small (papillary) muscles inside the heart and structures called chordae tendinae. (These are fibromuscular structures extending from the papillary muscles to the edge of the mitral and tricuspid valves.)

The volume of blood expelled by the heart is referred to as the cardiac output. This is usually calculated on the basis of the volume of blood expelled with each contraction of the heart (or stroke volume), multiplied by the number of times that the heart beats each minute.

Blood pressure is a measure of the force that results from the heart's pumping action. The highest (systolic) pressure occurs during contraction of the ventricles; the lowest (diastolic) pressure occurs during ventricular relaxation. When the blood pressure is too low, the patient is said to have hypotension. When blood pressure is too high, the patient is said to have hypertension.

The heart is suspended in a membranous sac called the pericardium. The fibrous pericardium (the strong outer portion of the sac) is firmly attached to the diaphragm beneath it, to the membrane lining the chest on each side and to the sternum (or breast bone) in front. The heart is covered by the visceral pericardium or epicardium. Between the heart and the epicardium lies the pericardial cavity, which is normally filled with a very small amount of pericardial fluid.

The pericardium can become irritated or inflamed following surgery. This condition is called pericarditis. This can be accompanied by an increase of fluid in the pericardial sac. If this fluid accumulates rapidly or in great amounts, the heart can become compressed by the fluid, a state called cardiac tamponade. The heart then has less ability to fill with blood and there is less cardiac output. Severe cardiac tamponade can cause a shock-like state that may be fatal. In such cases it is necessary to remove the fluid.

CONGENITAL HEART DISEASE

In the case of children, most heart problems are congenital—that is, they are problems the child is born with, as opposed to problems that arise from lifestyle or later activities. Congenital heart problems usually stem from abnormalities or defects in the structure of the heart. In such cases, the heart will not have formed properly. (Another term for a congenital heart defect is a ‘lesion.’) Some defects require treatment, while others will lessen in severity as the child grows and may not have to be treated.

Some pediatric cardiac surgical procedures can produce as close to a normal heart as is possible (for example, repairs of atrial or ventricular septal defects). Other operations cannot make the heart normal. The most that cardiac surgery can do for children with some congenital heart defects or lesions is to correct the blood circulation to ensure that most of the ‘blue blood’ (deoxygenated blood) goes to the lungs and most of the ‘red blood’ (oxygenated blood) goes to the body. However, the heart’s structure post-operatively can be far from normal. Therefore, while corrective heart surgery can allow for a significant improvement in lifestyle, it is not always usually curative in the sense of making the heart normal.

VENTRICULAR FAILURE

One of the main threats that children with these heart defects face is from heart failure. Heart failure occurs when the pumping capability of the heart is impaired and the ventricles are unable to pump an adequate volume of blood to the body and/or the lungs. This can affect either the left ventricle or the right ventricle or both (as in biventricular failure).

Left ventricular failure

With left-sided heart failure, blood backs up in the left ventricle and then progressively into the left atrium and into the lungs. Fluid will then build up in the lungs, making it more difficult for the blood to pick up oxygen. The patient will often be short of breath and breathe rapidly but shallowly, and may cough. Also, because the left ventricle is not pumping enough oxygenated blood out to the body, the skin may be cool

and appear bluish, and pulses will feel weak. There may be insufficient blood flow and oxygen delivery to the organs, which may also start to fail. For example, the kidneys may start to produce less urine and the patient may retain fluid and appear to gain weight.

Right ventricular failure

With right-sided heart failure, fluid builds up in the right ventricle, and then backs up into the right atrium and into the great veins (the IVC and the SVC). This leads to swelling, which may be seen in the ankles and across the backs of the hands and feet. The liver also often becomes swollen and enlarges so that it can be felt below the ribs of the right side of the chest.

Biventricular failure

Sometimes left-sided heart failure can lead to failure of the right side of the heart, as blood backs up through the lungs and into the right side of the heart. This places a strain on the right heart, which may then also fail.

SHUNTING

Shunting is the term applied when blood from the left and right sides of the circulation becomes mixed. The site at which shunting occurs and the amount of mixing will determine how much oxygenated blood is supplied to the tissues of the body. Normally, shunting is primarily from the side with the higher pressure to the side with the lower pressure: that is, from left to right. This may lead to changes in the right side, which then develops an increase in resistance to flow. The result is that the pressures on the left and right sides then become equal. This situation may become irreversible, preventing surgical corrections from being successfully undertaken.

PEDIATRIC HEART DEFECTS AND THEIR TREATMENT

The following section outlines the major heart defects that were diagnosed in the children whose deaths are under investigation in this Inquest.

PATENT DUCTUS ARTERIOSUS (PDA)

One of the heart problems diagnosed in these children was a patent ductus arteriosus. The ductus arteriosus is a blood vessel that is present in all babies before they are born. While in the womb, the lungs of the fetus cannot provide oxygen to the fetus's blood. Instead, the fetus receives its oxygen from its mother, through the umbilical cord. Because of that, the fetal lungs do not need to receive the volume of blood flow

that will be required after birth. The ductus arteriosus connects the pulmonary artery to the aorta, allowing blood to bypass the lungs. Normally the ductus arteriosus closes on its own within a few days of birth as the lungs begin to strengthen and provide the body with the oxygen it requires. Once it is closed it is referred to as a ligamentum arteriosus.

Occasionally, the ductus may not close on its own and remains open (or, in medical terms, patent). This condition is called a patent ductus arteriosus (PDA). In some babies, a procedure known as a PDA ligation must be performed to close (or, in medical terms, to ligate) the PDA and prevent blood from flowing through it. Otherwise, if the ductus arteriosus remains patent, the newborn may develop congestive heart failure from the increased pulmonary blood flow.

Sometimes closure of the ductus is not a positive development if the baby suffers from other defects that prevent adequate blood flow to either the lungs or body. Then the patent ductus may provide an alternative and necessary route for blood flow. In these babies, a drug (prostaglandin) can be given to keep the ductus open.

SEPTAL DEFECTS

The most common pediatric cardiac problems result from defects in the wall separating the right and left sides of the heart. The wall is called the septum, while the defects are referred to as septal defects. The wall between the atria is called the atrial septum and the wall between the ventricles is called the ventricular septum. A defect in the wall between the atria is referred to as an ASD, or atrial septal defect, and a defect in the wall between the ventricles is called a VSD, or ventricular septal defect. The defect can range from a small hole in the septum to a significant portion of the septum actually being missing. When there is such a defect, shunting can occur.

If blood flows from the right side of the heart to the left, the child may appear blue because of the lack of oxygen in the blood. The medical term for this reduced oxygen supply is cyanosis, and a baby with blue colouring is described as being cyanotic. With some septal defects, blood may actually flow back and forth between the right and left sides of the heart.

Some VSDs occur at a higher point on the septal wall, where the septum is thinner. These are referred to as perimembranous VSDs. Those VSDs that occur at a lower point on the septal wall, where the septum is

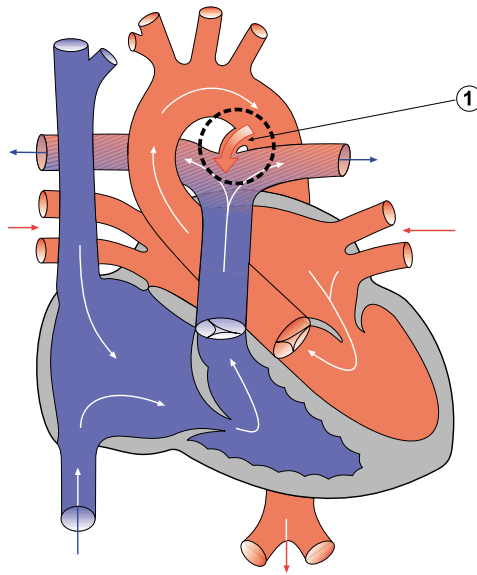


Diagram 2.4 Patent ductus arteriosus

1 – open or patent ductus arteriosus

The shunt or abnormal flow is from aorta to pulmonary artery as indicated by the shaded red arrow.

The diagrams illustrating pediatric heart defects demonstrate general blood flow, but are not representative of any specific point in the heart's cycle.

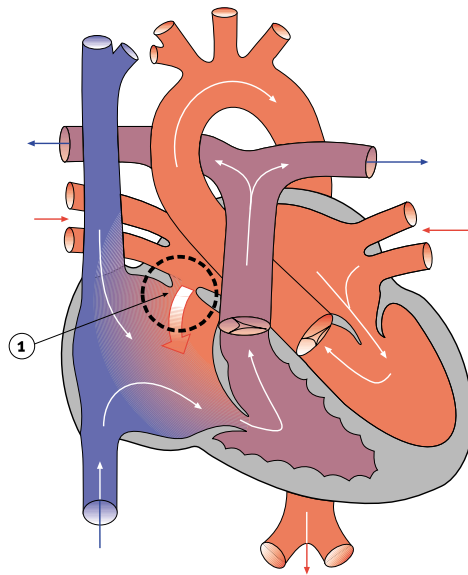


Diagram 2.5 Atrial septal defect (ASD)

1 – atrial septal defect

The shunt or abnormal flow is from left atrium to right atrium as indicated by the shaded red arrow.

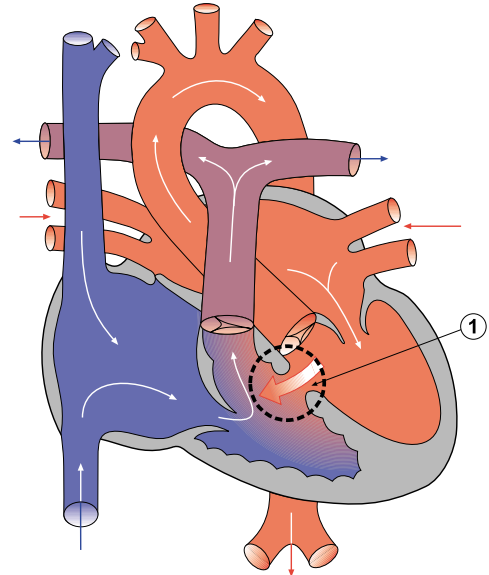


Diagram 2.6 Ventricular septal defect (VSD)

1 – ventricular septal defect

The shunt or abnormal flow is from left ventricle to right ventricle as indicated by the shaded red arrow.

thicker, are called muscular VSDs, which may be single or multiple. Other VSDs occur just below the aortic valve and are referred to as subaortic VSDs.

Some ASDs and VSDs can heal or close on their own, but in a significant number of patients, surgery is required to repair them. Repairs can take the form of a suture (or stitch) being used to close the opening if it is small enough, or a patch actually being sewn over the opening in the case of larger defects. Such patches are usually made of the patient's own pericardium or inert material such as teflon. Pericardial tissue is preferred, since it stands a smaller chance of infection or rejection and can usually grow along with the heart itself.

TETRALOGY OF FALLOT

Tetralogy of Fallot involves four defects within the heart. The first is a hole in the ventricular septum or a VSD. Second, the aorta, which is normally attached to the left ventricle, is wrongly positioned overtop the ventricular septum (and is termed an overriding aorta). Third, there is thickening (in medical terms, hypertrophy) of the muscle of the right ventricle (referred to as right ventricular hypertrophy). The fourth condition is a partial or complete obstruction of blood flow from the right ventricle (also termed RVOT—right ventricular outflow tract obstruction). This most often results from pulmonary narrowing (or, in medical terms, stenosis).

Pulmonary stenosis is a narrowing of the vessels carrying blood from the right ventricle to the lungs. This narrowing is caused by an underdevelopment of the area around the lung valve and along the pulmonary arteries, and can range from a blockage at the valve to thickening below the valve. There can also be

narrowing of the pulmonary artery above the valve, and the vessel can narrow into both of the branches that go to the lungs.

To provide relief for the lack of blood flow created by the pulmonary stenosis, it is usually necessary to insert a small tube as an artificial shunt. This shunt then connects the aorta (or one of its branches, such as the subclavian artery) to one of the pulmonary arteries. The best size for the shunt will depend on the size of the patient, as well as the specific structure of the patient's heart and blood vessels.

Such shunts are often referred to as Blalock-Taussig shunts, after the surgeons who developed them, and are used in a variety of pediatric cardiac procedures. Depending on the artery to which the shunt is connected, they are known as either classic or modified Blalock-Taussig shunts.

Children with Tetralogy of Fallot are often referred to as Tet babies. Some children with this condition also suffer from weight loss or fail to gain weight (known medically as failure to thrive). Other Tet babies suffer Tet spells or periods when they are extremely cyanotic. Symptoms include anxiety, air hunger, respiratory distress, increasing cyanosis and an altered level of consciousness. The symptoms are most often brought on by activity. Tet spells usually indicate an urgent need for repair of the heart defect.

The operation to correct Tetralogy of Fallot consists of removing the outflow tract obstruction and patching the VSD. Care must be taken not to damage the heart's electrical conduction system because of the nature of the operation. Damage to the heart's electrical conduction system can interfere with the heart's ability to beat properly.

Most often, complete correction of the lesions is performed, even in newborns. Palliative procedures are reserved for those patients with extremely abnormal hearts, such as those with severe underdevelopment (hypoplasia) of the pulmonary arteries and certain abnormalities of the coronary arteries. (A palliative procedure is one that alleviates the current problem but is not a definitive repair and does not usually offer a long-term good outcome.)

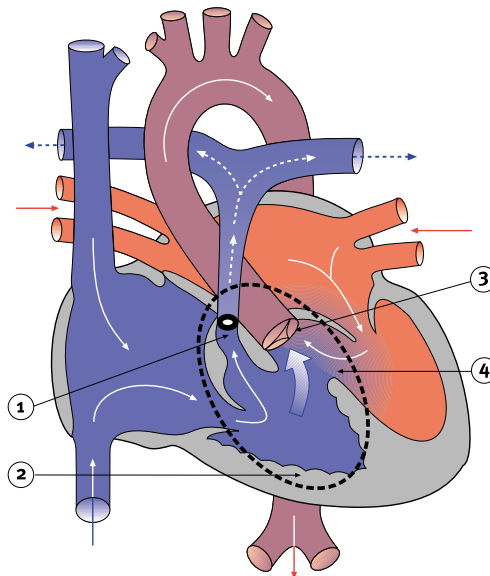


Diagram 2.7 Tetralogy of Fallot

- 1 – pulmonary stenosis (a form of right ventricular outflow tract obstruction)
- 2 – right ventricular hypertrophy
- 3 – overriding aorta
- 4 – ventricular septal defect

The degree of pulmonary stenosis controls the flow patterns. The shaded blue arrows show blue blood mixing with red blood. The broken white arrows indicate diminished blood flow through the pulmonary artery.

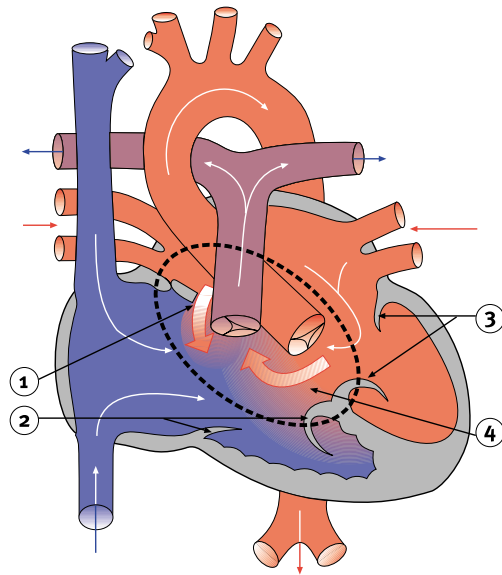


Diagram 2.8 Atrioventricular (AV) canal defect

- 1 – atrial septal defect
- 2 – abnormal tricuspid valve
- 3 – abnormal mitral valve
- 4 – ventricular septal defect

The shunt or abnormal flow is from left atrium to right atrium, left ventricle to right ventricle (as indicated by the shaded red arrows). Tricuspid and mitral valve regurgitation occurs as a result of the abnormal tricuspid and mitral valves.

The shunt (or abnormal flow) back into the heart's right side. There, the oxygen-rich blood mixes with the oxygen-poor venous blood from the body and is sent back to the lungs. This results in the heart pumping an extra amount of blood and working harder than it should. In time, the extra work causes the heart to enlarge. There is also an associated increase in the pressure in the pulmonary artery, which may cause problems.

With complete AV canal defects, signs and symptoms occur early in infancy. These usually include abnormal heart sounds, congestive heart failure, intermittent cyanosis, respiratory infections, poor feeding and inadequate weight gain.

In a baby with severe symptoms or high pulmonary artery pressure, surgery must usually be done in infancy. The surgeon closes the hole with one or two patches. The single valve is then divided between the atria and the ventricles to make two separate valves. Again, care must be taken not to damage the heart's electrical conduction system.

ATRIOVENTRICULAR CANAL DEFECT

Atrioventricular (AV) canal defect is a large hole in the centre of the heart. The defect is situated where the septal wall between the upper chambers (atria) joins the septal wall between the lower chambers (ventricles). In addition, the tricuspid and mitral valves (the atrioventricular valves), which normally separate the heart's upper and lower chambers, are not formed as individual valves. Instead, one large valve bridges the defect.

Complete AV canal defect, also known as an atrioventricular septal defect or endocardial cushion defect, is often associated with other cardiac defects, such as Tetralogy of Fallot. The complete AV canal defect is commonly found in children with Down's syndrome. An incomplete or partial form of AV canal defect, known as an ostium primum atrial septal defect, involves only the atrial septum.

The AV canal defect lets some of the oxygen-rich blood from the heart's left side pass (or